Lab. 9

Benign Bone neoplasm

OSTEOMA

- benign tumors composed of mature compact or cancellous bone.

- Osteomas are essentially restricted to the craniofacial skeleton and rarely, if ever, are diagnosed in other bones.

- The common palatal and mandibular tori and buccal exostoses are not considered to represent osteomas, although they are histopathologically identical to osteomas.

- Because many osteomas are small, asymptomatic lesions, there is little reliable information as to their true frequency.

- The lesion may arise on the surface of the bone as a polypoid or sessile mass **(periosteal osteoma)** or may be located in the medullary bone **(endosteal osteoma**).

- Periosteal osteomas appear as slowly growing masses on the surface of the mandible or maxilla. Some types may reach a large size, resulting in facial deformity.

- Small endosteal osteomas are asymptomatic, but large lesions cause a slowly progressive enlargement of the affected area.

- An osteoma involving the mandibular condyle may cause a slowly progressing shift in the patient's occlusion, with deviation of the midline of the chin toward the unaffected side.

- Paranasal sinus lesions also are possible and are actually more common than gnathic lesions.

- The frontal sinus is most commonly involved, followed by the ethmoid and maxillary sinuses. asymptomatic, although pain, swelling, sinusitis, and nasal discharge are possible

HISTOPATHOLOGIC FEATURES

Compact osteomas are composed of normal- appearing dense bone showing minimal marrow tissue.

Cancellous osteomas are composed of trabeculae of bone and fibrofatty marrow.

Osteoblastic activity may be fairly prominent.

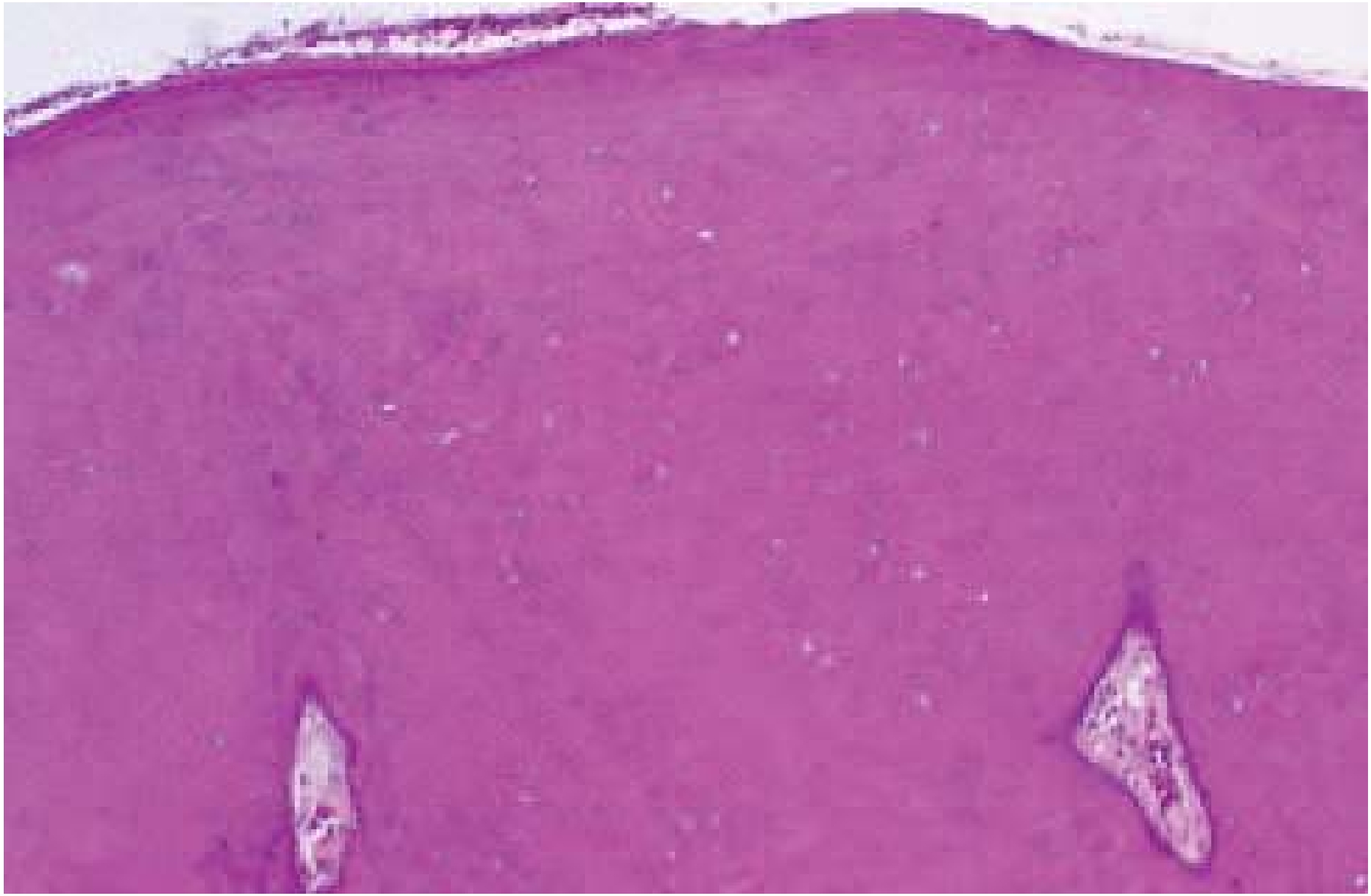

compact osteoma is composed
of dense bone, with only minimal marrow elements.

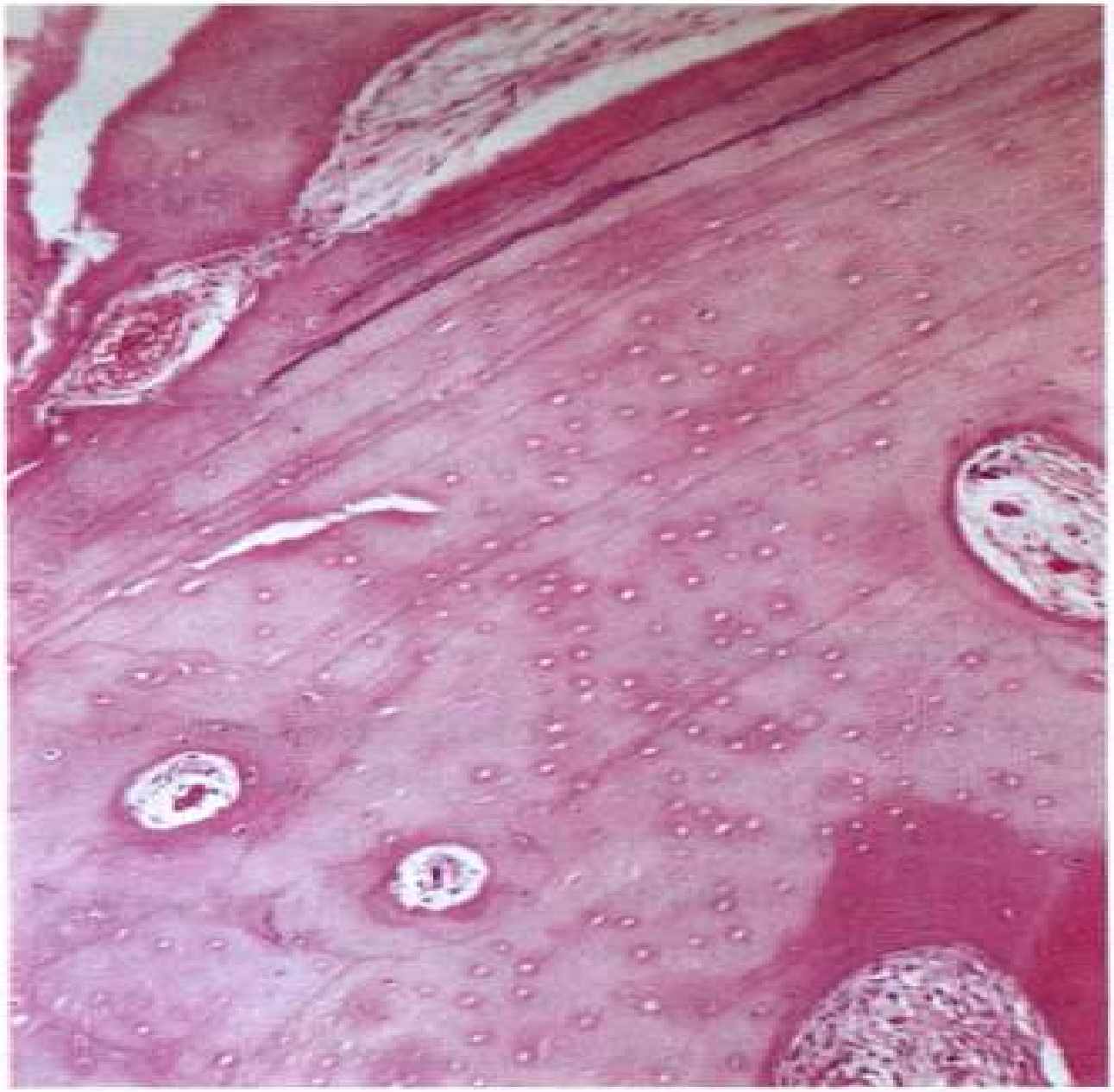

Fig. 9.4 Compact osteoma. Dense bone is laid down in lamellae with occasional vascular spaces, but there is no attempt to form Haversian systems.

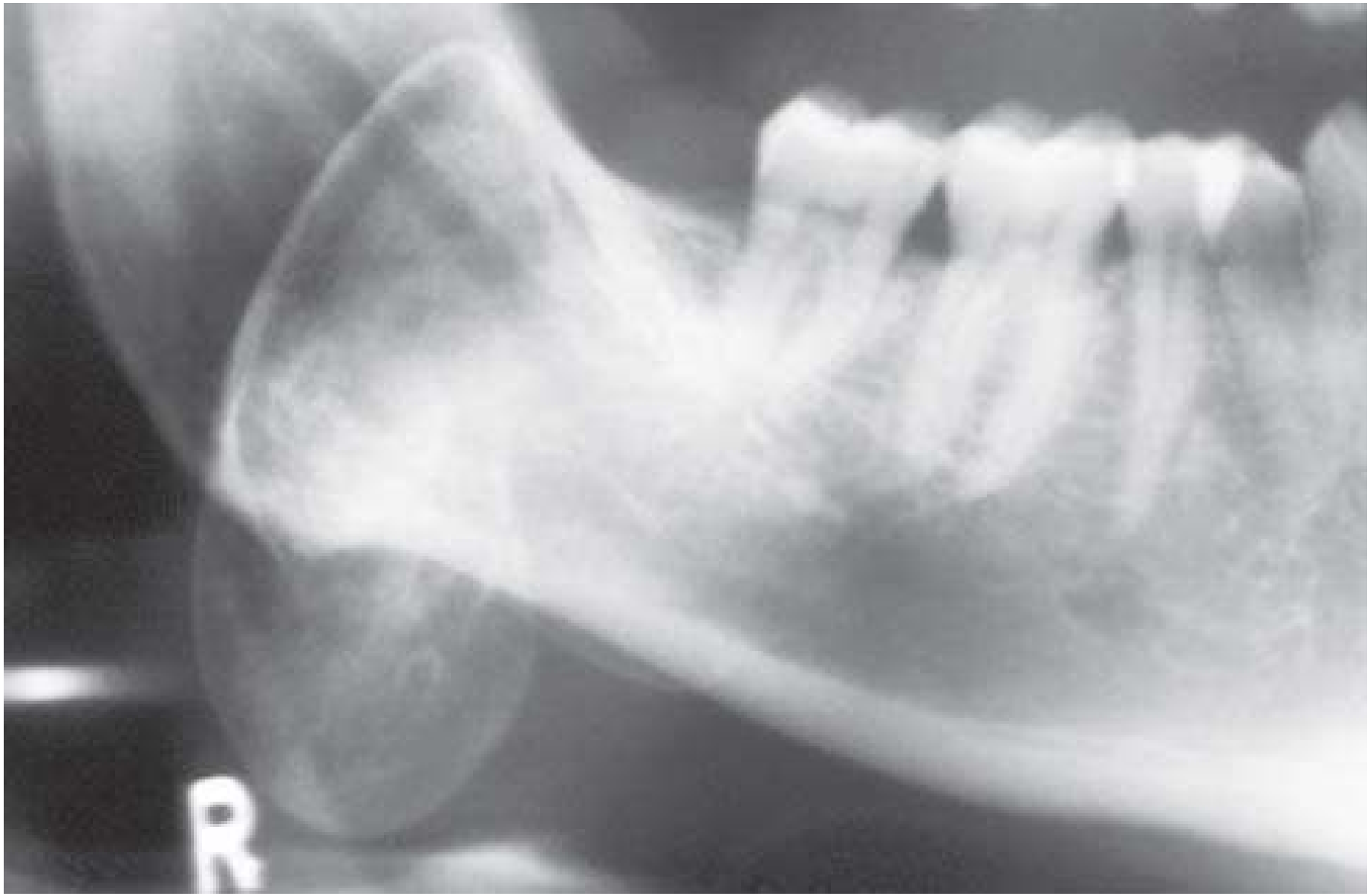

The radiograph shows a pedunculated cancellous osteoma arising from the lingual surface of the mandible near the crest of the alveolar ridge.

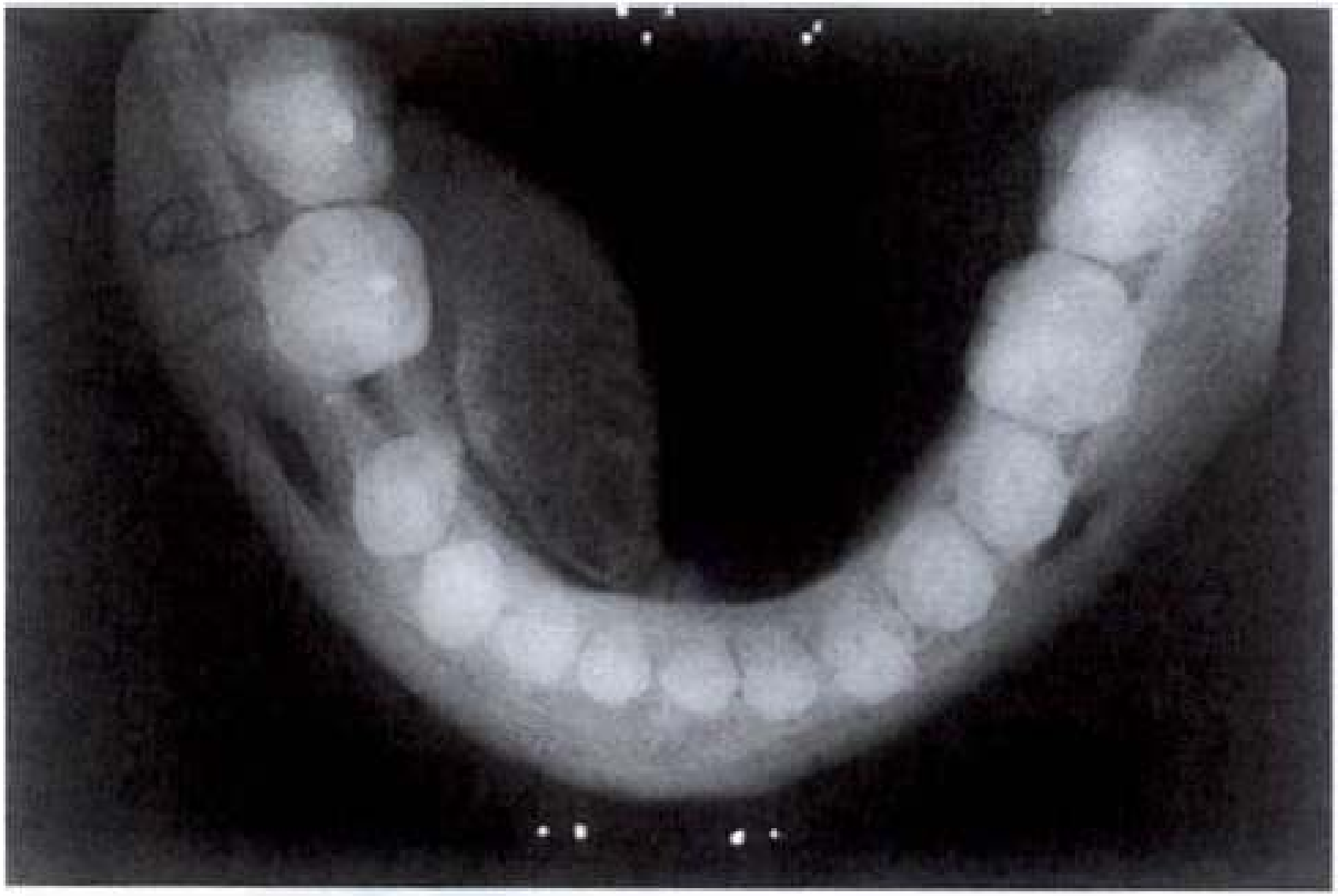

Fig. 9.5 Cancellous osteoma of the mandible. The tumour has arisen from a relatively narrow base lingually to the molars but has been moulded forward during growth by pressure of the tongue. The trabecular pattern of cancellous bone can be seen. A torus mandibularis arises further forward on the jaw, arises from a broad base and is usually bilateral.

GARDNER SYNDROME

- rare disorder that is inherited as an autosomal dominant trait approximately one third of cases occur spontaneously and appear to represent new gene mutations.

- colonic polyps typically develop during the second decade; because these are adenomatous, they ultimately transform into adenocarcinoma.

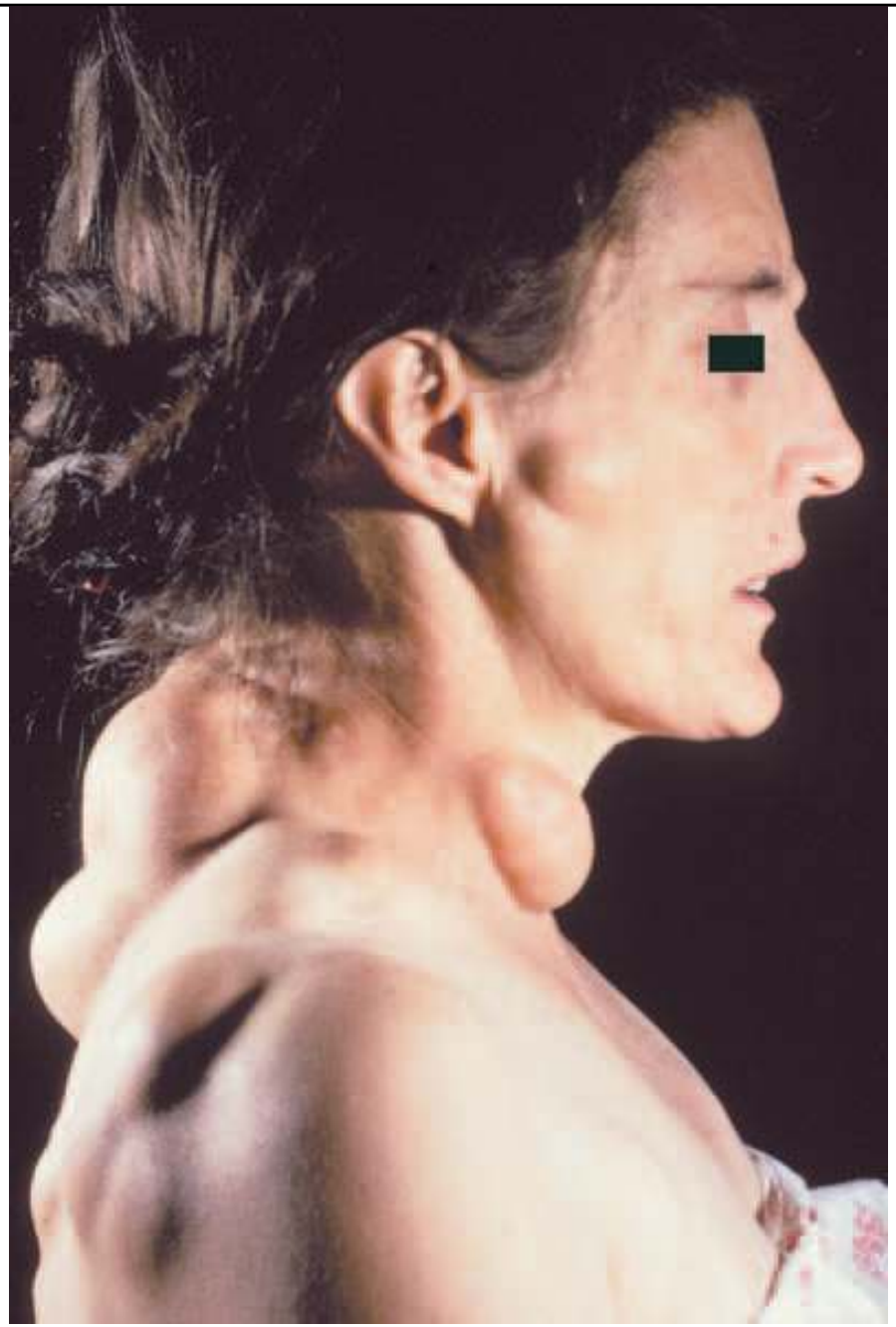

This patient has multiple, large epidermoid cysts.

- Up to 90% of patients with Gardner syndrome demonstrate skeletal abnormalities, the most common of which are osteomas.

- Although the osteomas may affect any part of the skeleton, the most commonly involved areas are the skull, paranasal sinuses, and the mandible.

- Dental abnormalities include an increased prevalence of odontomas, supernumerary teeth, and impacted teeth.
- Most patients show one or several epidermoid cysts of the skin .
- Desmoid tumors (locally aggressive fibrous neoplasms) of the soft tissue arise in approximately 10% of affected patients.

- Panoramic radiograph showing multiple osteomas of the

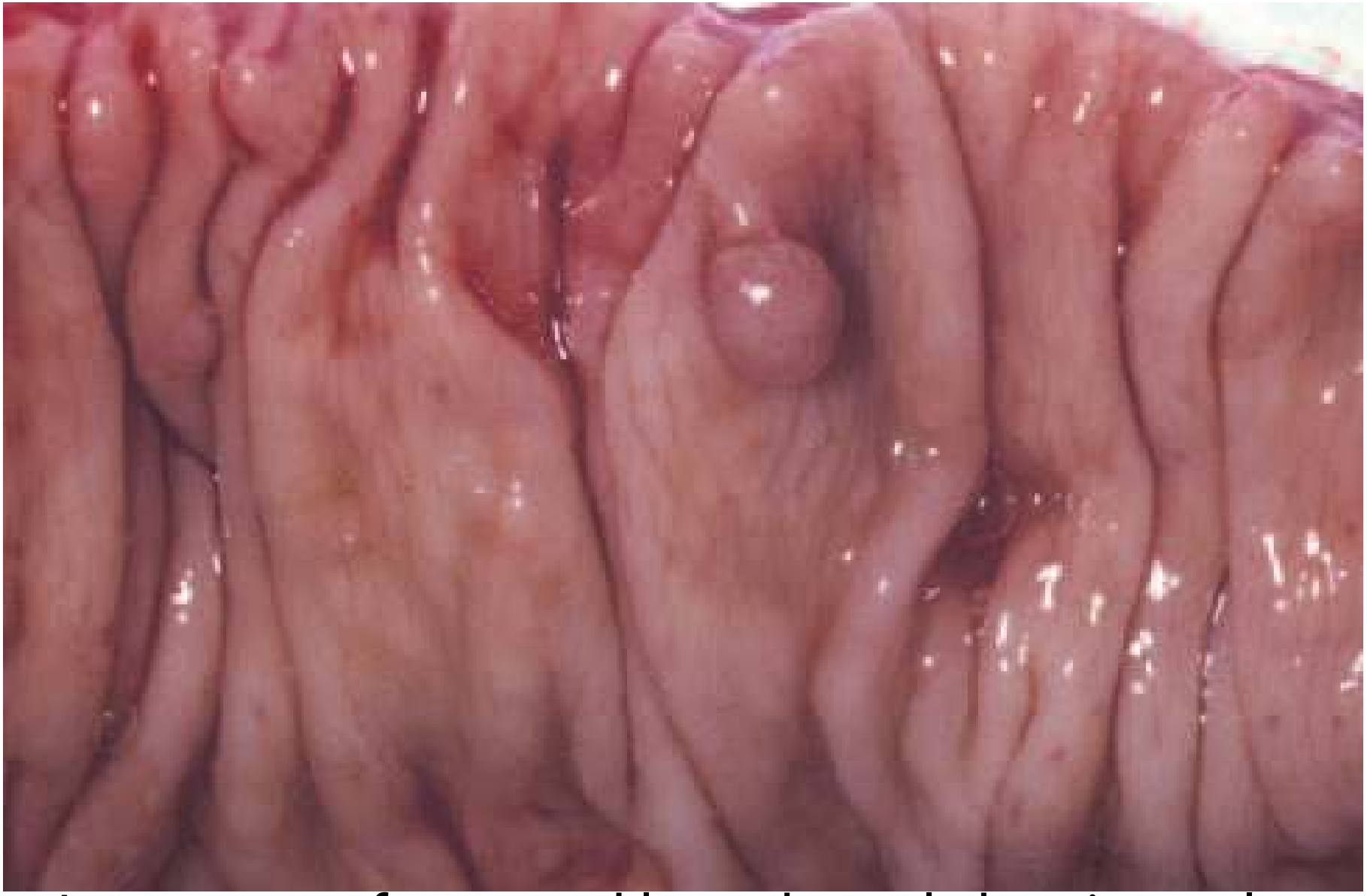

A segment of resected large bowel showing polyp formation

OSTEOBLASTOMA AND OSTEOID OSTEOMA

- Is a benign bone bone neoplasm that is found more frequently in patients between 10 and 30 years of age.

- The tumor produces prostaglandins that result in signif i- cant pain that is relieved by prostaglandin inhibitors such as aspirin.

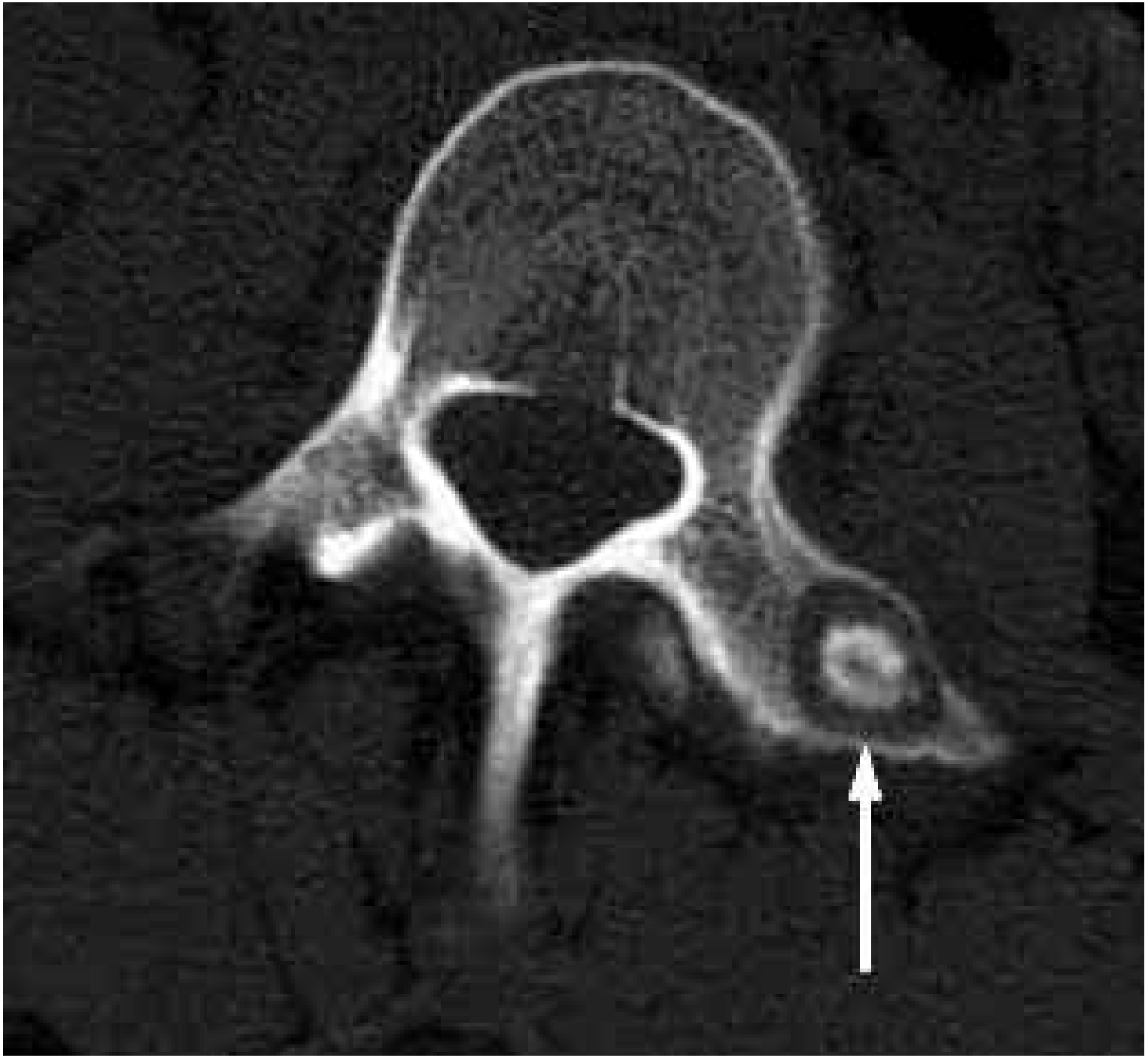

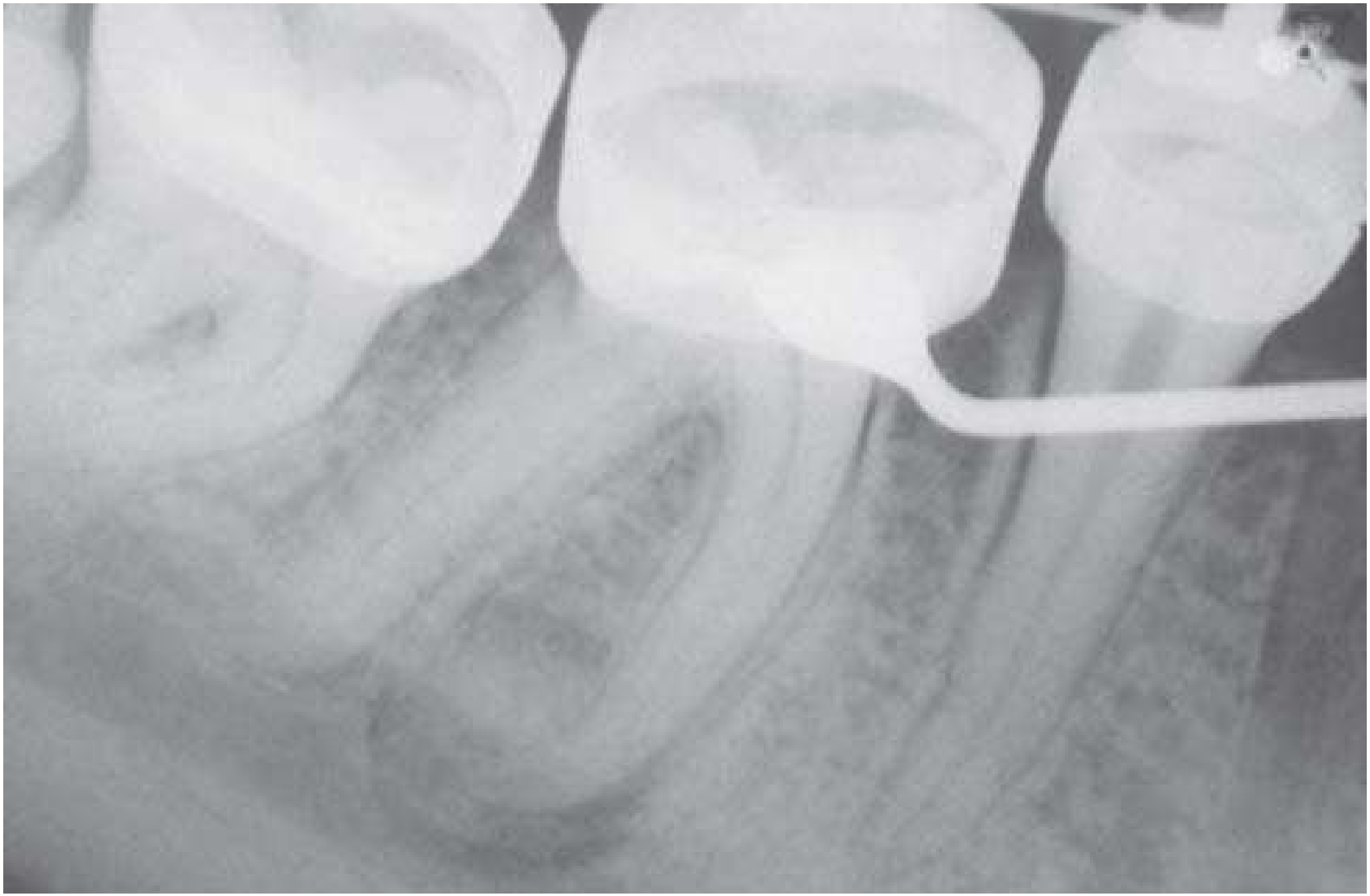

A circumscribed, mixed radiolucent and radiopaque lesion near the apex of mesial root of mandibular fi rst molar. The patient had dull, nocturnal pain that was relieved by aspirin.

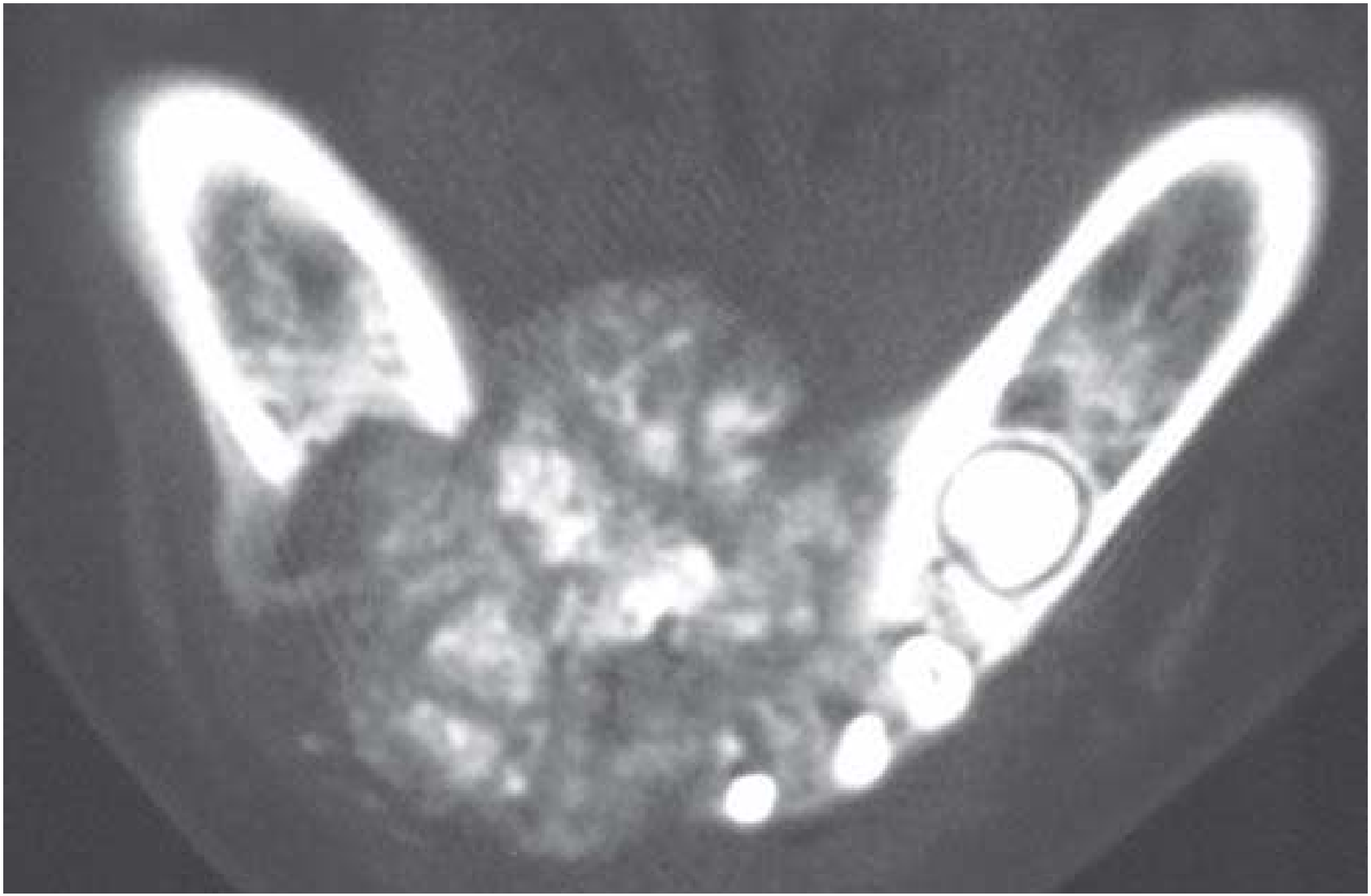

Computed tomography (CT) image showing a large, destructive radiolucent and radiopaque lesion of the mandible.

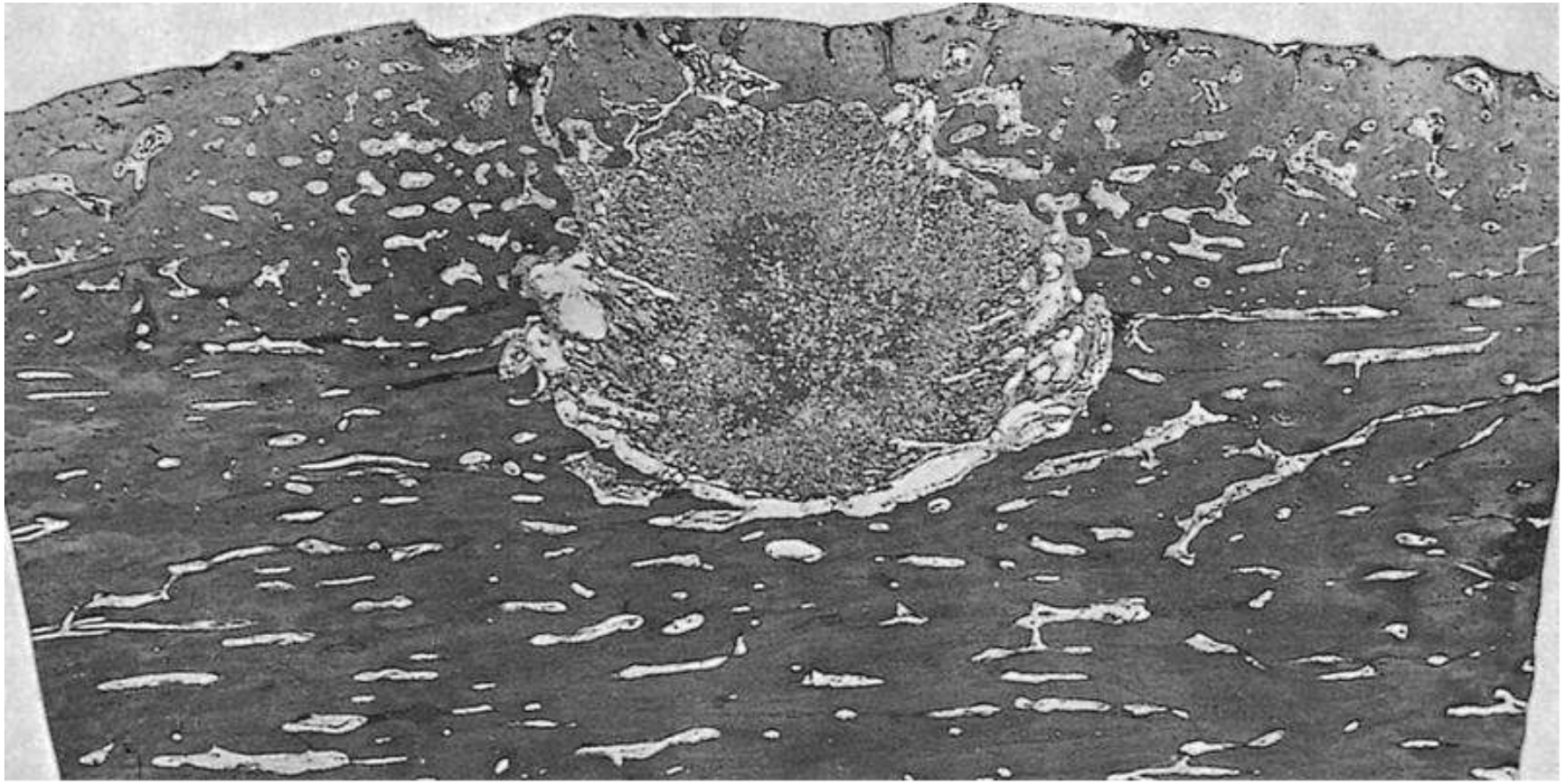

OSTEOID OSTEOMA

This whole mount section from the femur of a 22-year-old man demonstrates densely sclerotic cortical bone surrounding the intact nidus of an osteoid osteoma. (Fig. 116 from Fascicle 5, 2nd Series.)

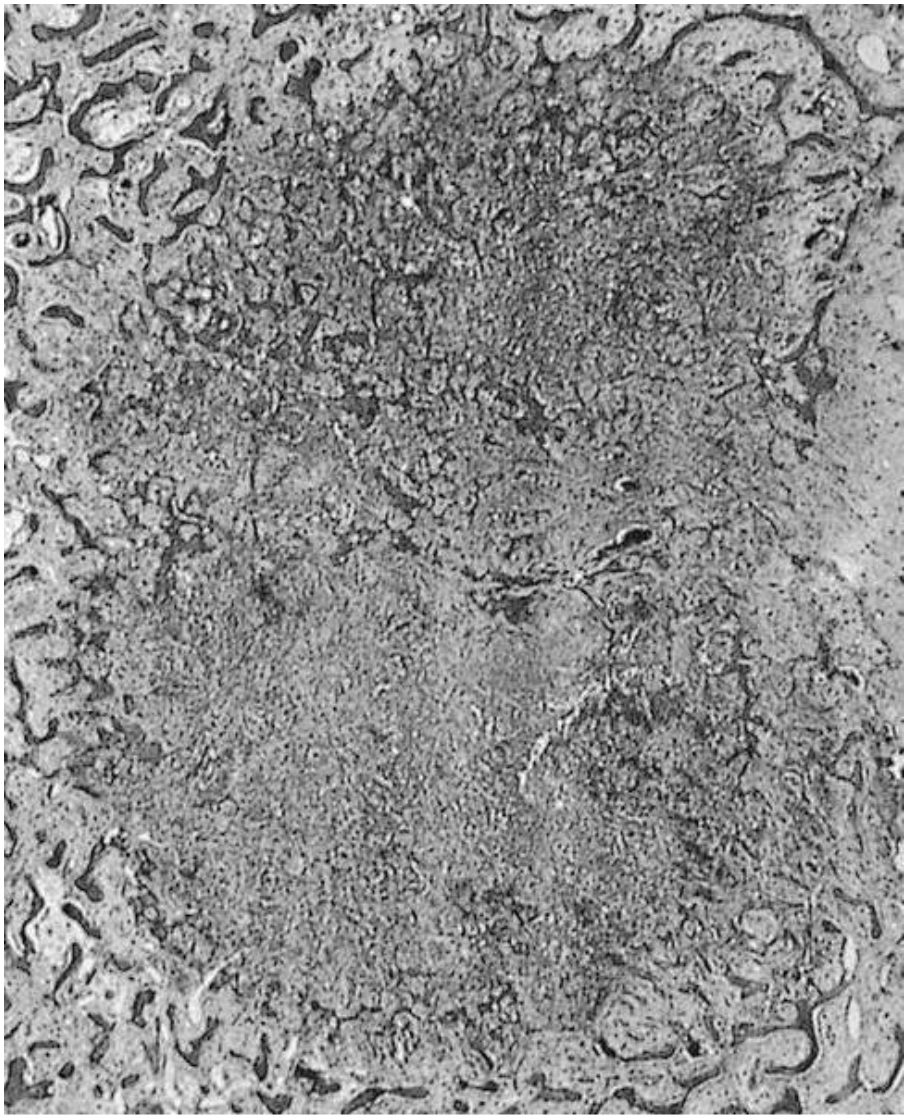

OSTEOID OSTEOMA

Irregular bony trabeculae and a highly vascular fibrous stroma characterize this intact nidus. The surrounding bone is not sclerotic. (Fig. 121 from Fascicle 5, 2nd Series.)

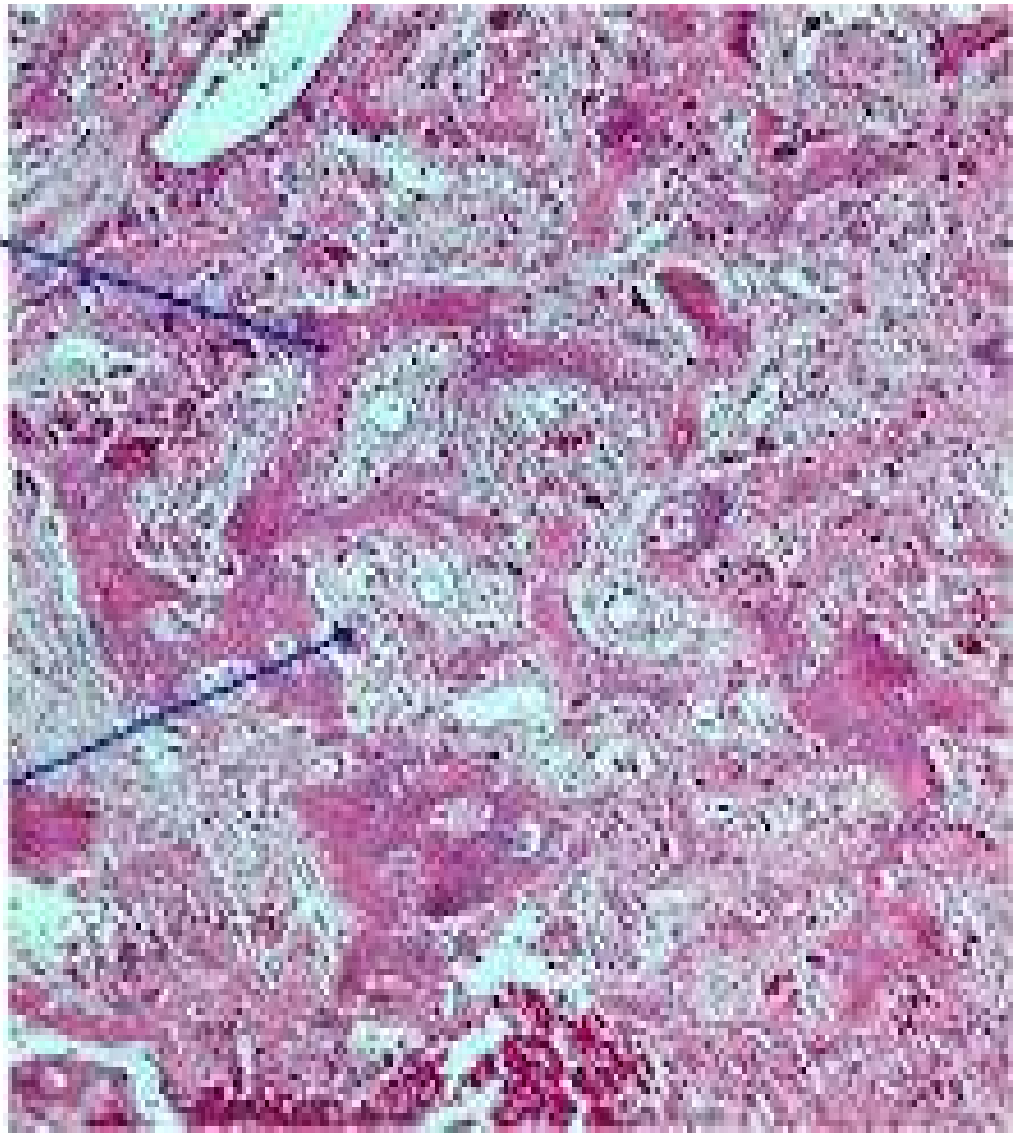
Trabeculae of
Woven Bone Lined
by Osteoblasts
Fibrovascular Stroma

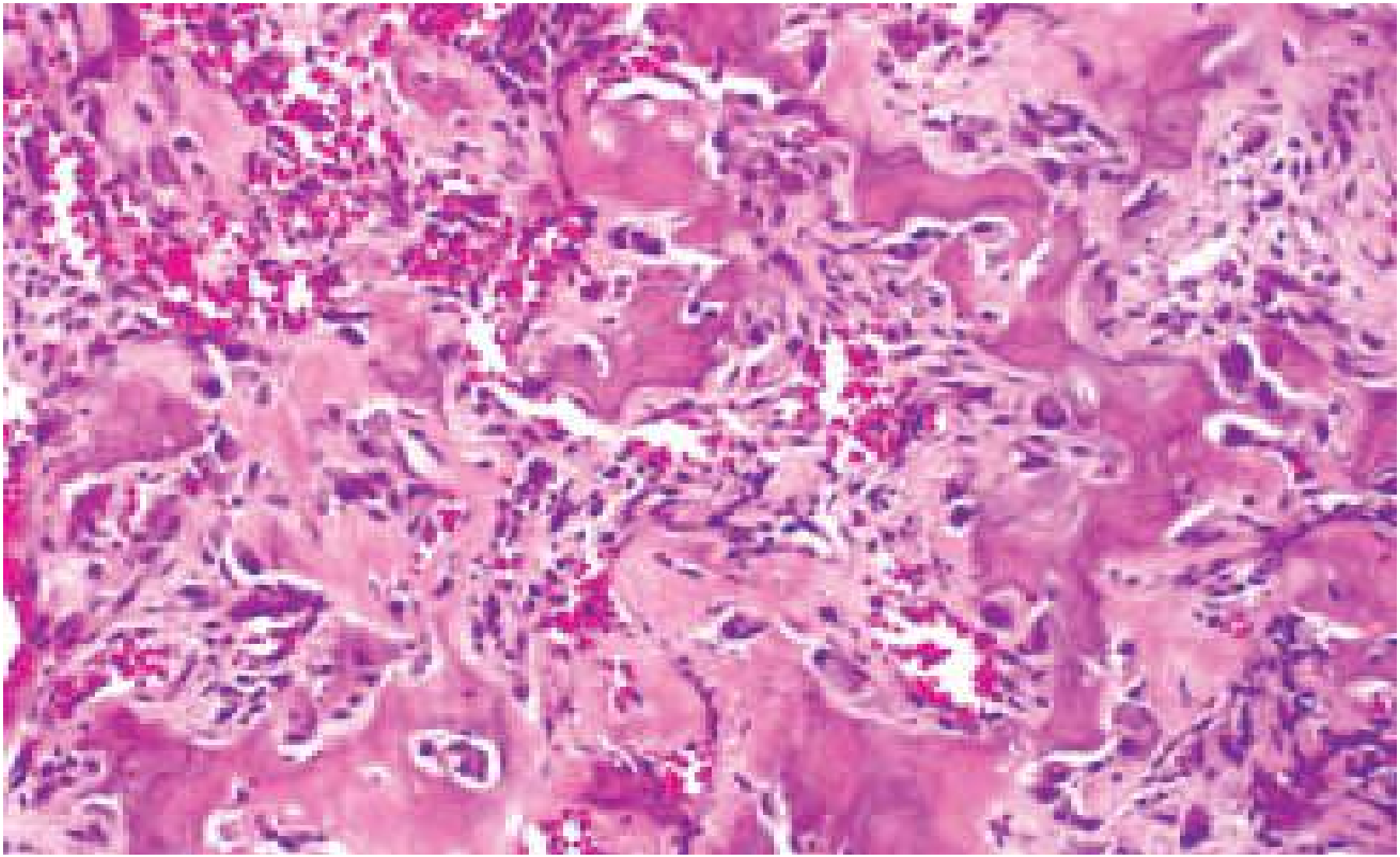

Osteoblastoma. High-power photomicrograph showing irregular bony trabeculae with prominent osteoblastic rimming and osteoclasts.

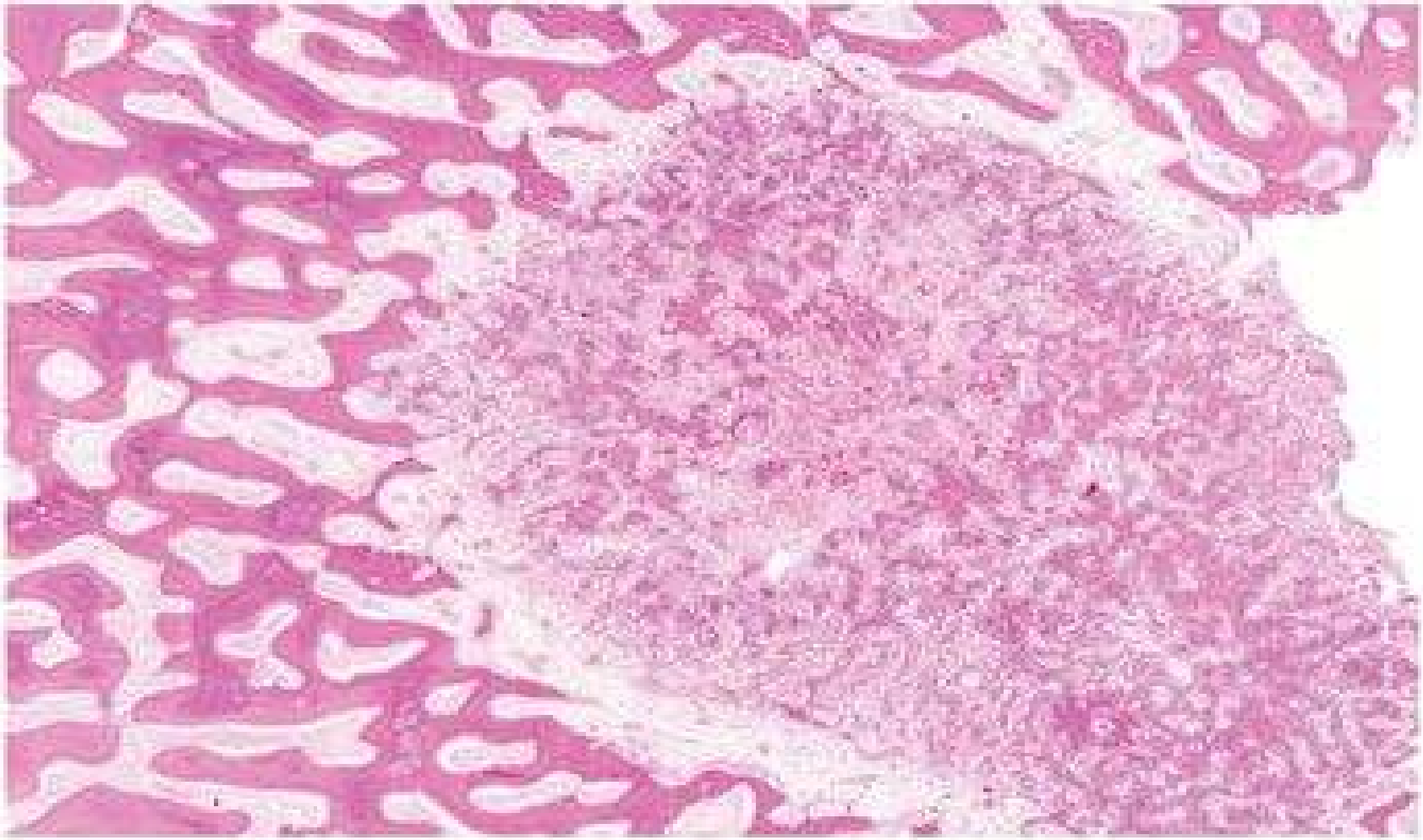

FIGURE 8.30 Osteoid osteoma. The lesion is characterized by a well-demarcated nidus (*right*) surrounded by reactive bone formation (sclerosis) and loose fibrovascular tissue.

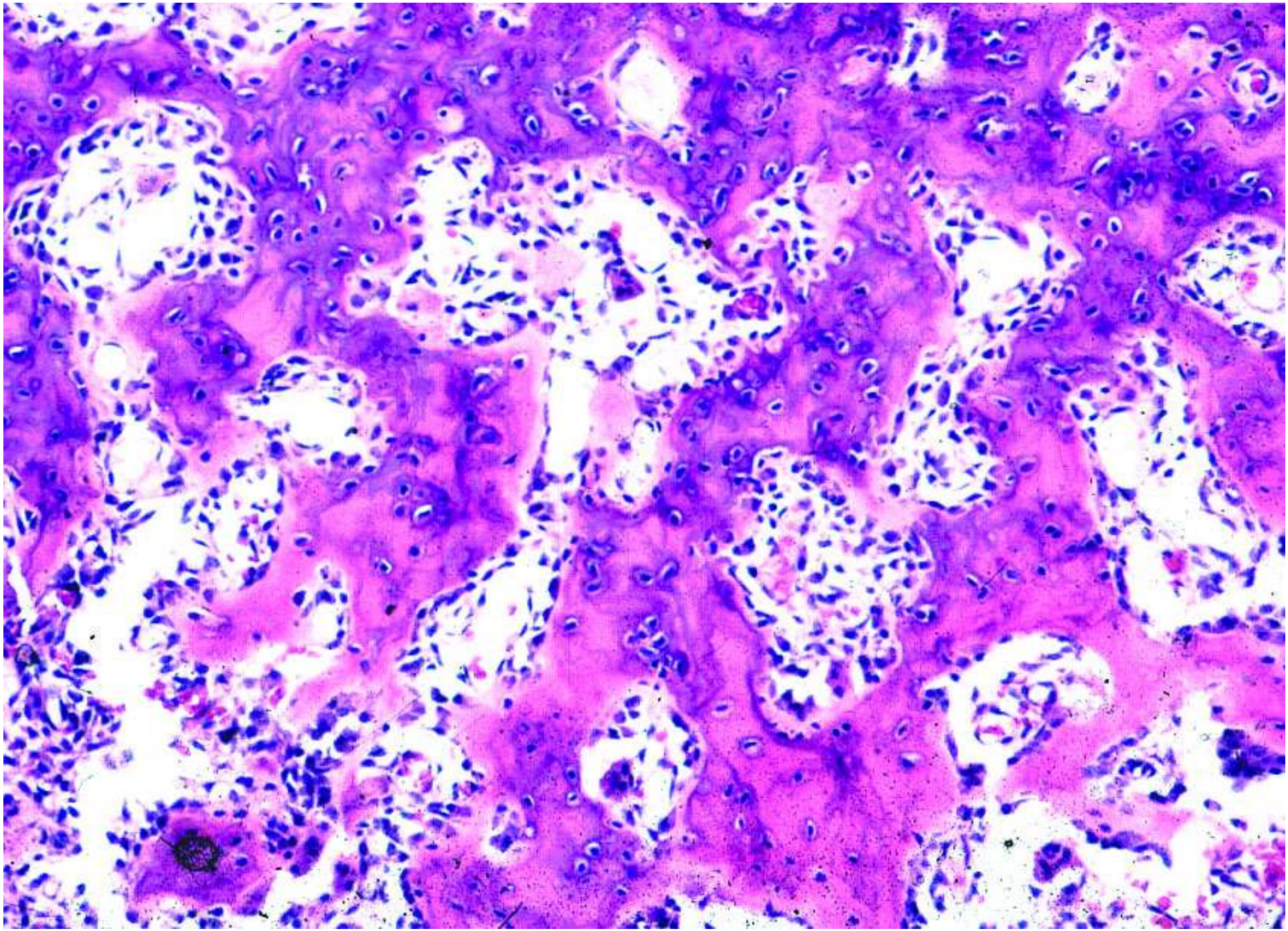

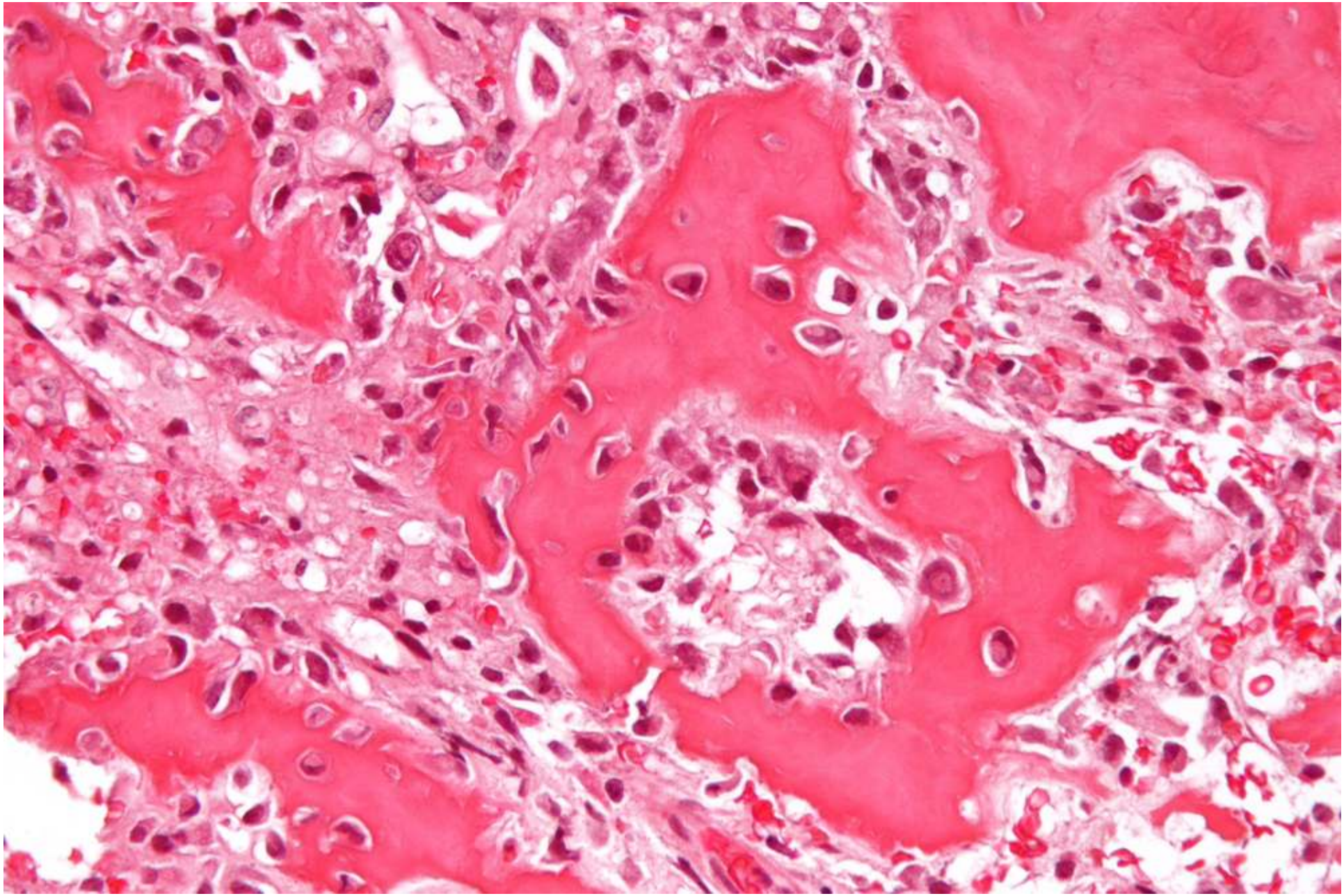

DESMOBLASTIC FIBROBLASTOMA

High power view of Desmoplastic Fibroblastoma

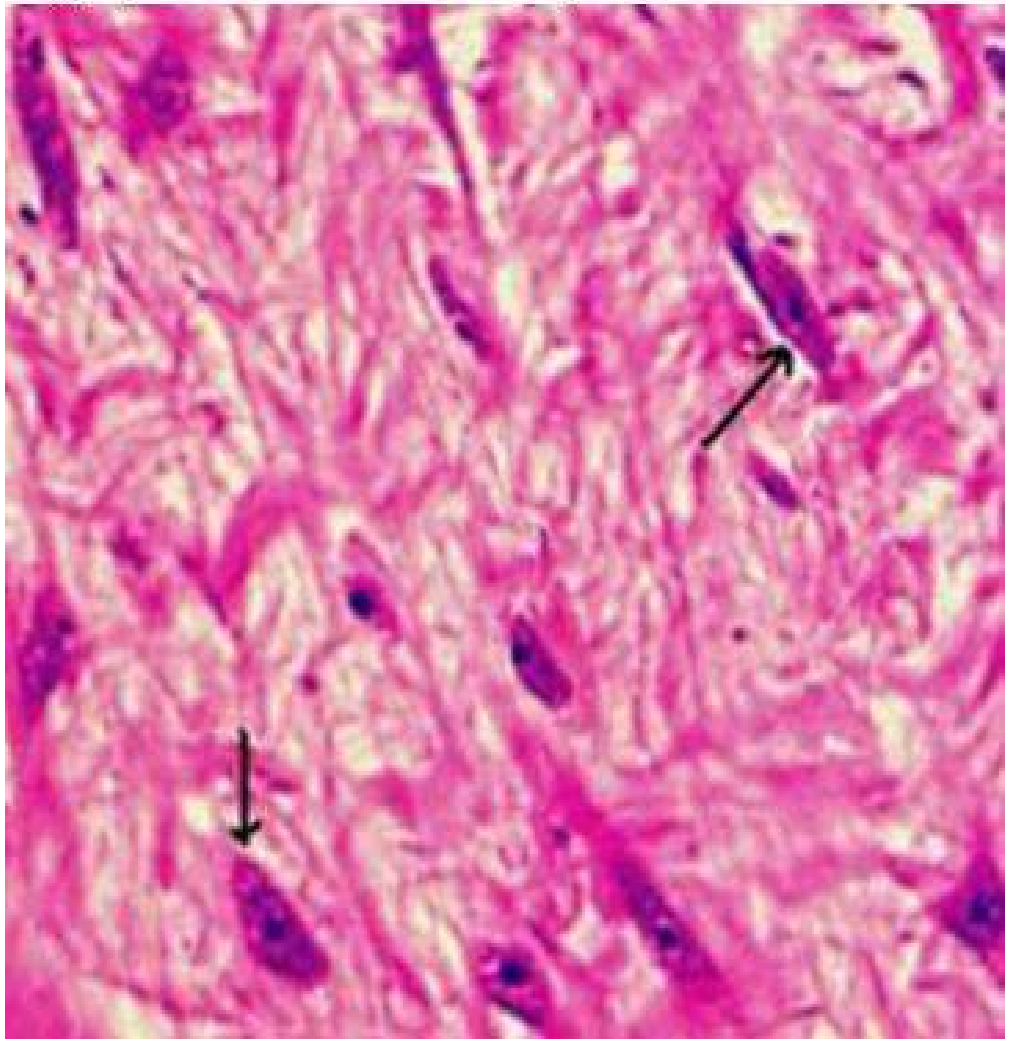

Hemangioma of bone

- It's a rare intraosseous vascular malformation that when seen in the jaws, can mimic both odontogenic and non-odontogenic lesions.
- Difficulty in controlling hemorrhage in a notable complication during surgical intervention.
- Half cases occur in the mandible in the posterior region.
- A firm slow growing expansion of the mandible or maxilla.
- Spontaneous gingival hemorrhage around the teeth maybe noted.
- Parasthesia and vertical mobility.

Hemangioma of bone showing **honey comb radiographic** pattern with associated root resorption.

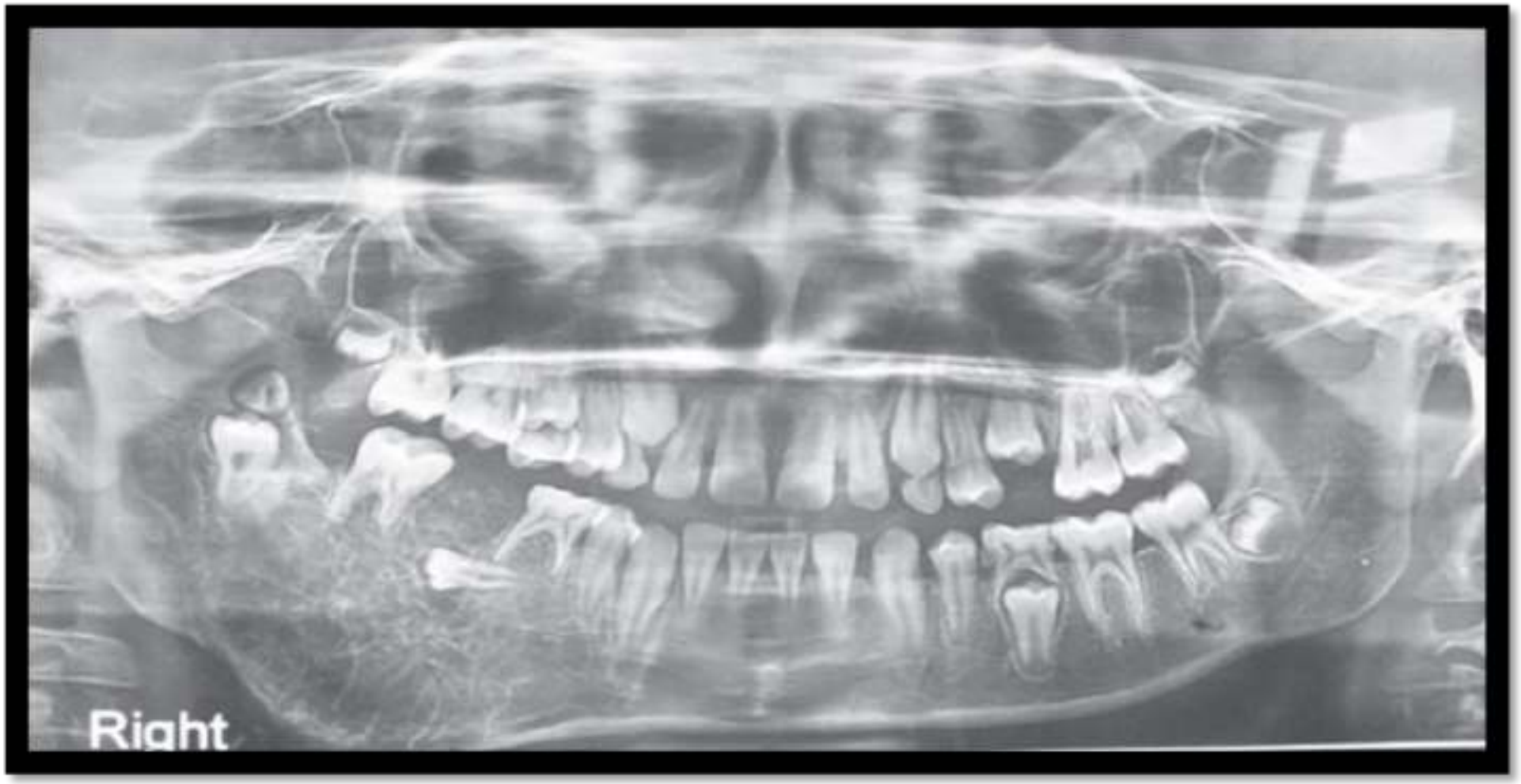
Right

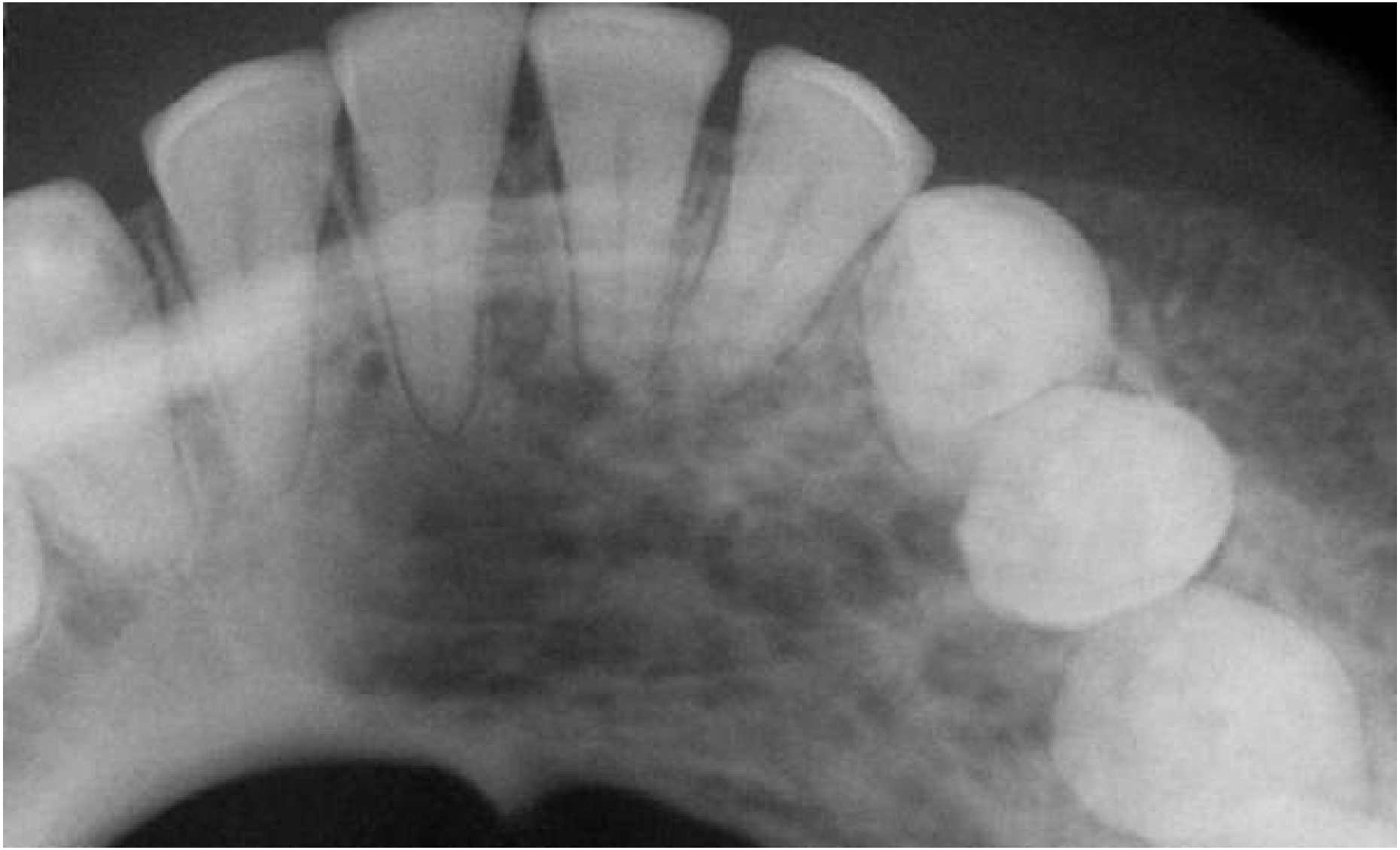

Hemangioma

Lip lesion: haemangioma

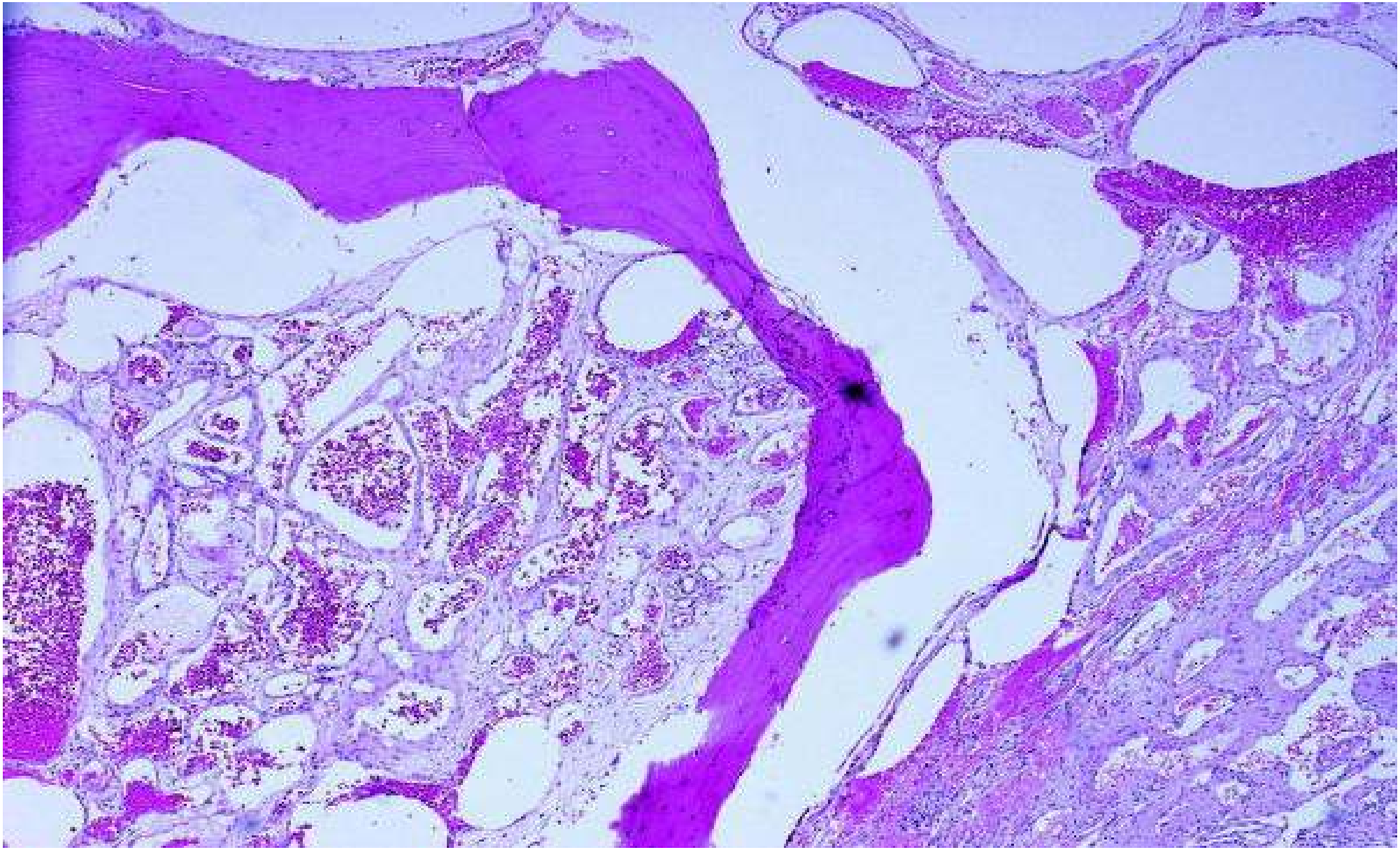

Hemangioma of bone. Note numerous vascular channels surrounded by trabeculae of bone.

THE
END
My best wishes
for you
Dr. Rawaa Al-
Ubaidy